

A Case-based Experience That Helped Form Who I Am As A Cardiac Care Provider....

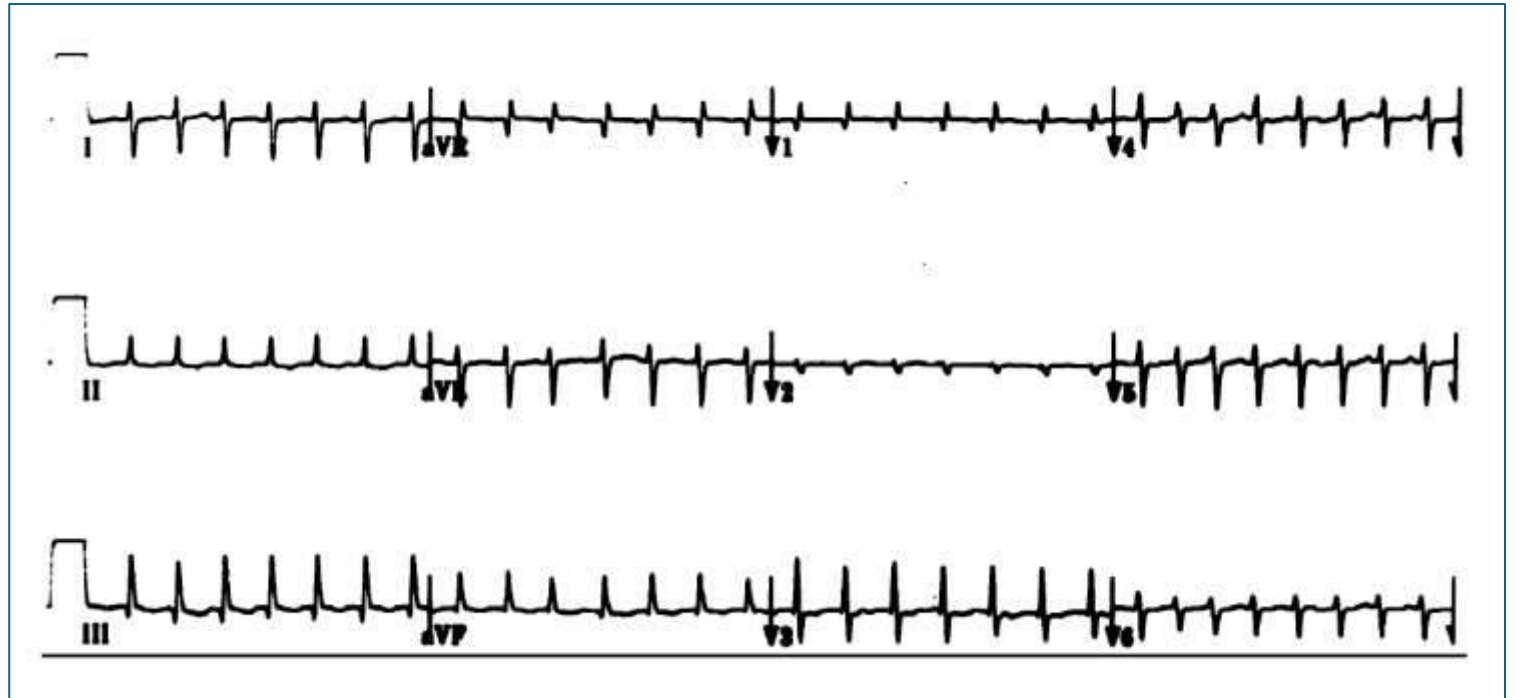
Jack Rychik

Children's Hospital of Philadelphia

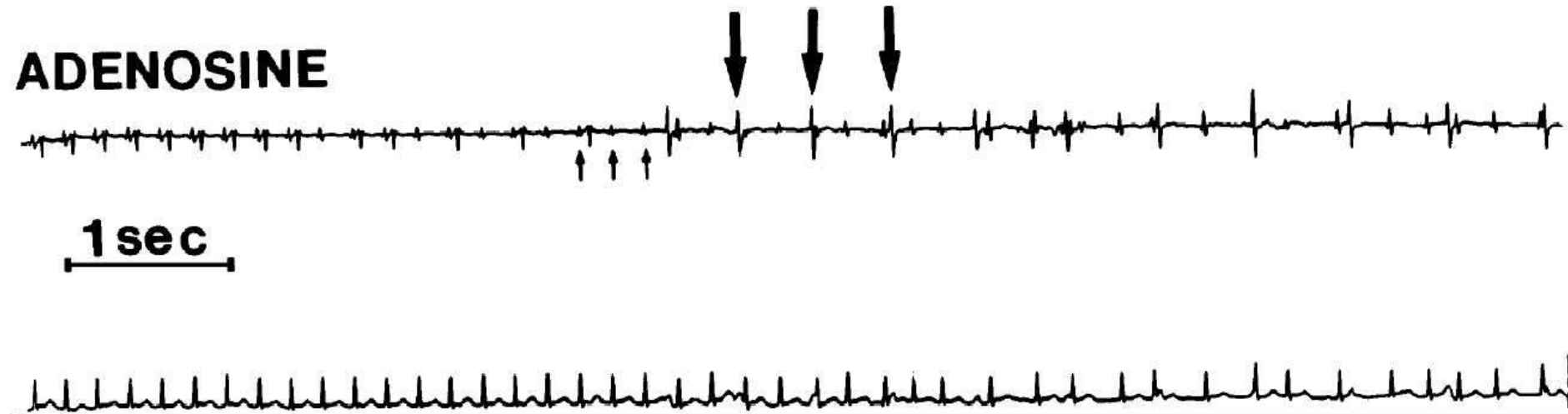
August 1992

The Case...

- 36 weeks gestation, partial abruption
Apgars 2, 7
- Fever developed day 3, tachycardia noted 240-270 bpm

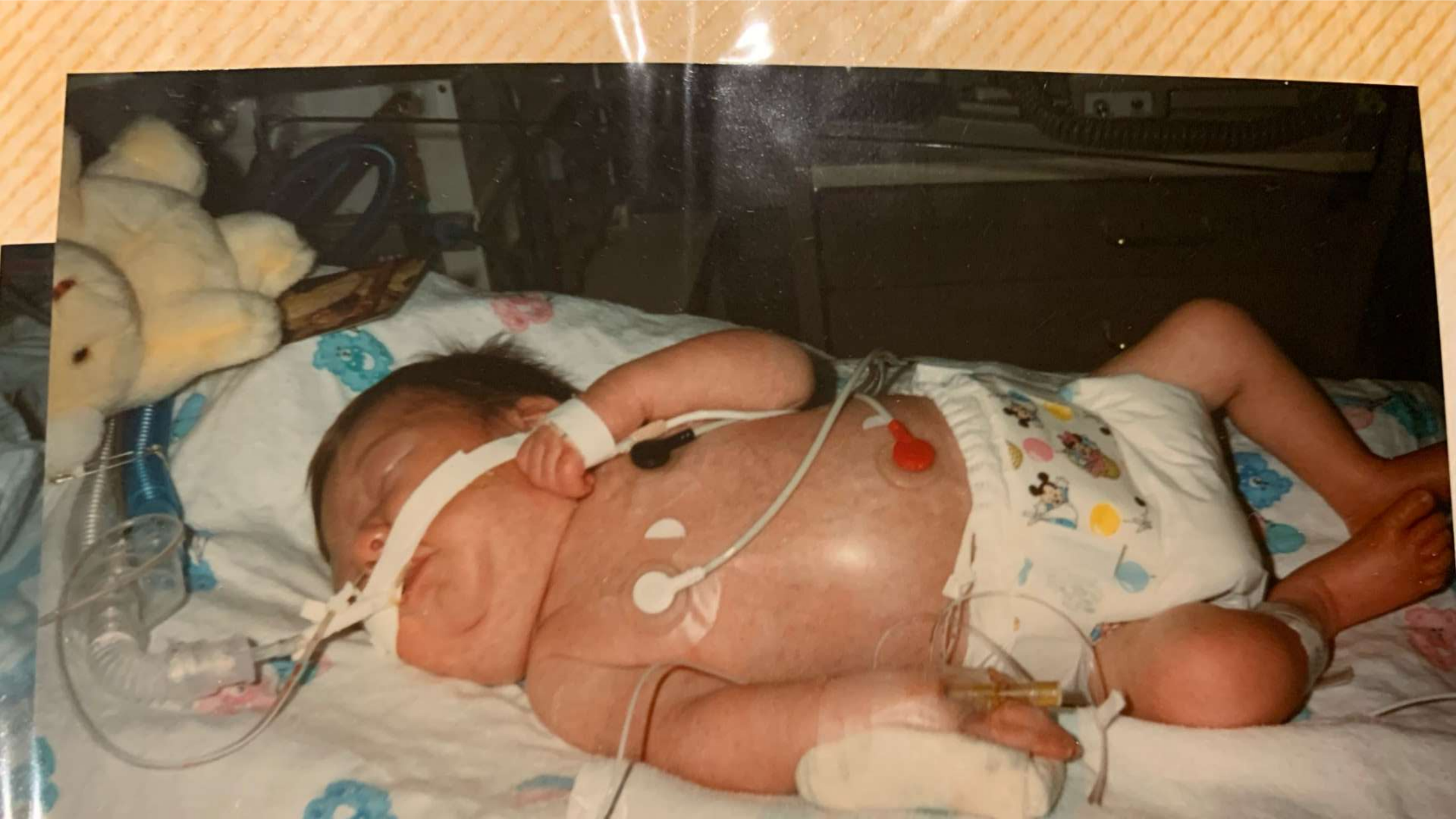

- No slowing of the rate in response to facial ice or adenosine
- Transesophageal lead dropped and adenosine administered



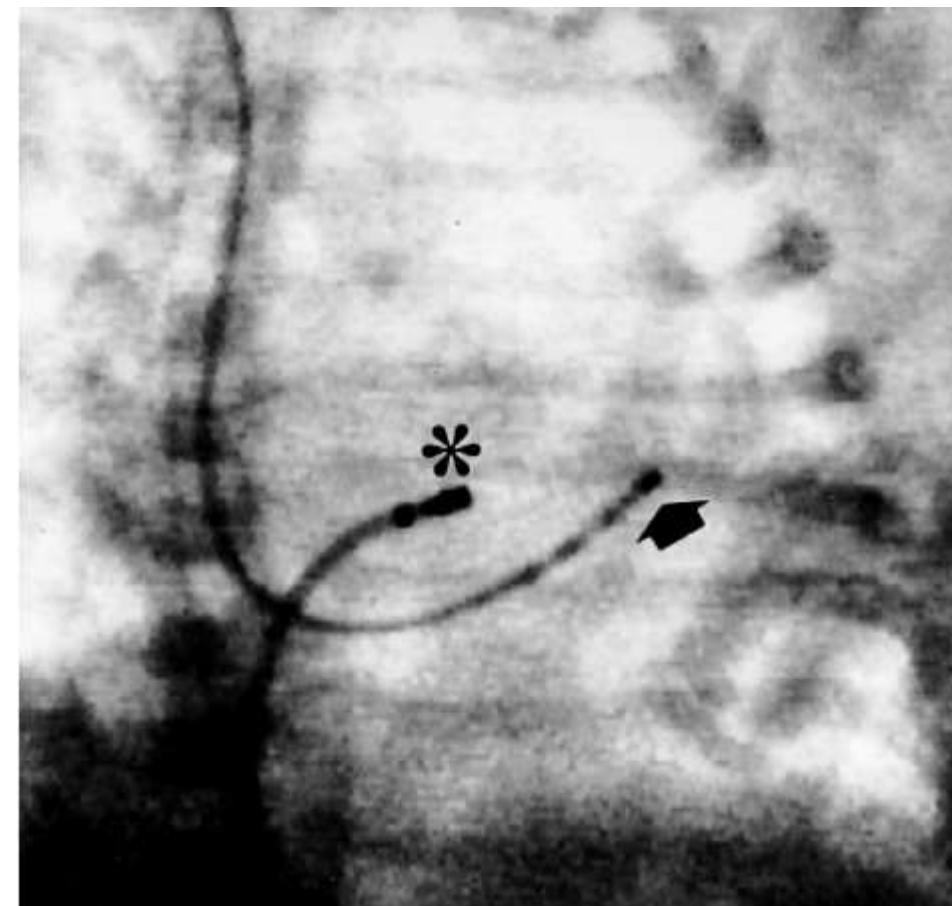

Congenital Junctional Ectopic Tachycardia!

- External surface cooling
- Intravenous Digoxin, Procainamide
- No slowing...ventricular dysfunction, heart failure and anasarca develop
- Two episodes of ventricular fibrillation, successfully converted via DC current cardioversion
- Procainamide & Digoxin dc'd, Amiodarone started
- Persistent tachycardia 260 bpm, Esmolol infusion started
- Persistent hypotension, acidosis [bicarbonate infusion started]
- Now 9 days of failed therapy heart rate still >250 bpm....



August 1992

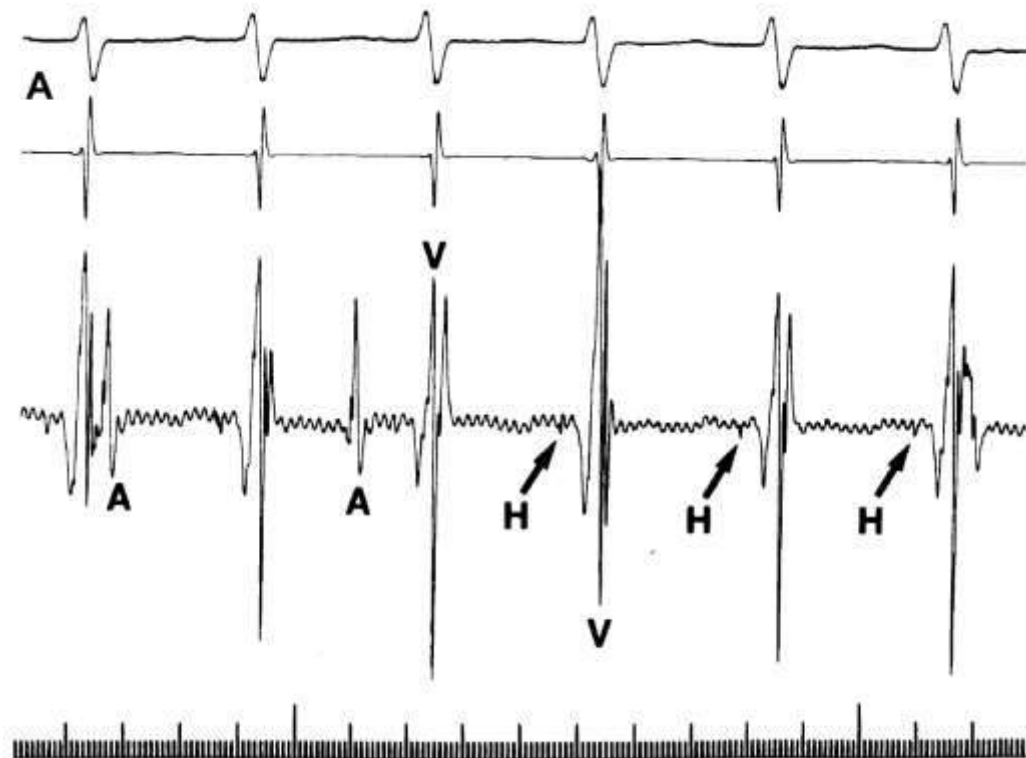



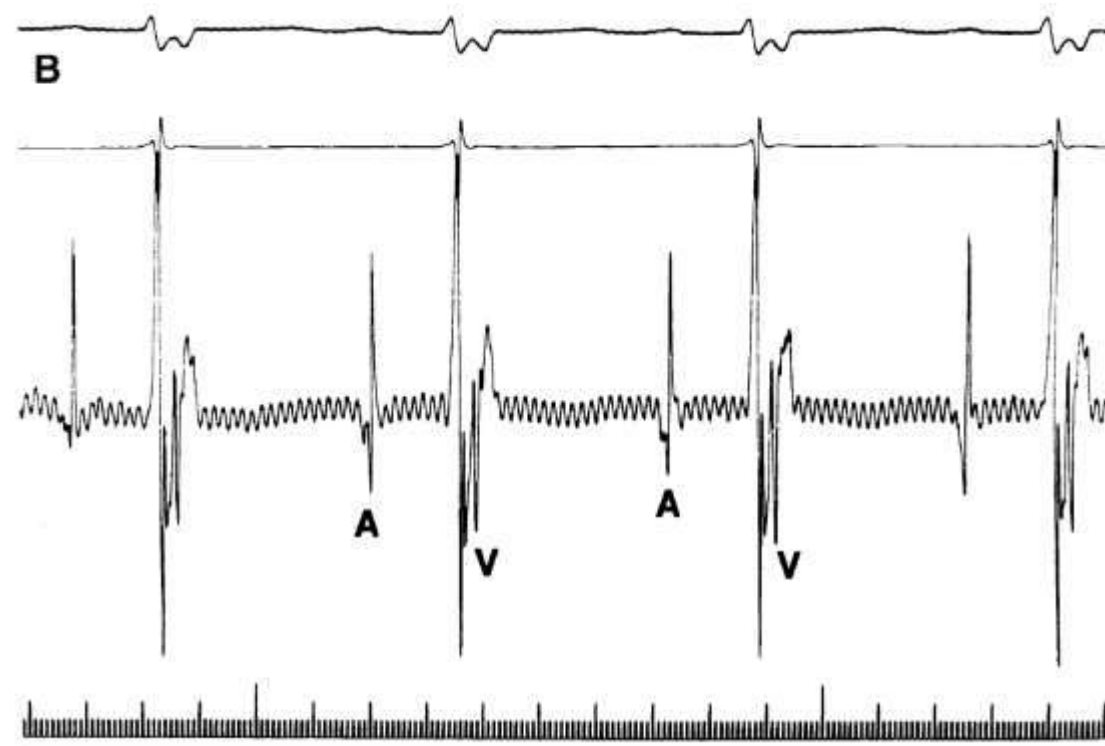
15 watts of energy at 20 secs, impedance of 130 ohms

10 watts of energy at 50 secs, impedance of 113 ohms

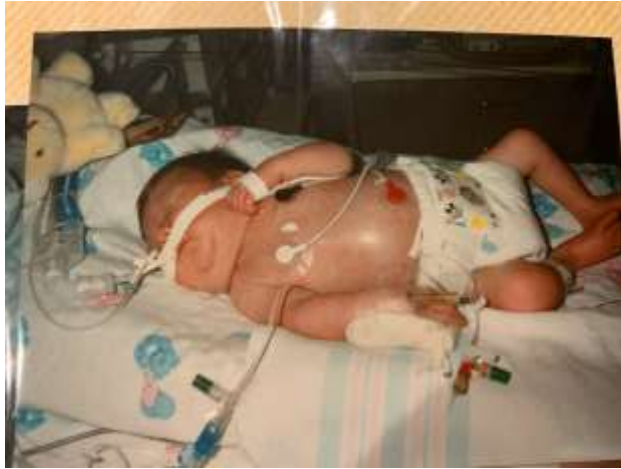Electrograms from His Bundle RF Catheter



JET



Normal Sinus Rhythm!



Pediatr Cardiol 18:447-450, 1997

Pediatric Cardiology

© Springer Verlag New York Inc. 1997

Transcatheter Radiofrequency Ablation for Congenital Junctional Ectopic Tachycardia in Infancy

J. Rychik,^{1,2} F.E. Marchlinski,³ T.L. Sweeten,^{1,2} C.I. Berul,^{1,2} A.M. Bhat,⁴ C. Collins-Burke,^{1,2} V.L. Vetter^{1,2}

¹Division of Cardiology, The Children's Hospital of Philadelphia, 34th Street and Civic Center Boulevard, Philadelphia, PA 19104, USA

²Department of Pediatrics, The University of Pennsylvania School of Medicine, Philadelphia, PA 19104, USA

³Philadelphia Heart Institute, Presbyterian Medical Center, Philadelphia, PA 19104, USA

⁴A.I. Dupont Institute, Medical Center of Delaware, 1800 Rockland, Wilmington, DE 19899, USA



30 Years Old!

Permission to Show Photo Granted by Patient

Optimism

Persistence

Boldness

(often confused with arrogance or stupidity)

Don't Ever Shy Away From Getting Help!