

CARDIOLOGY
2024

Syncope in a teenager

Thomas Glenn, MD

Assistant Professor
Texas Children's Hospital



Syncope in a teenager

Patient GM, 13-year-old female

- | | | |
|----|---------------------------------------|--|
| 1. | June 2021: Syncope while swimming | |
| 2. | June 2022: Syncope while swimming | Seen by outside cardiologist and cleared |
| 3. | June 2023: Near syncope at volleyball | |
| 4. | July 2023: Near syncope in the pool | |
| 5. | September 2023: Syncope at volleyball | |

3 lifetime episodes of exertional syncope / 2 near episodes

Syncope in a teenager

Patient GM, 13 year old female

- Cousin (maternal side) who had sudden death, thought to be overdose as young adult, but details largely unknown
- Normal vital signs and physical examination
- Normal echocardiogram
- Normal ECG with normal QTc

Syncope in a teenager

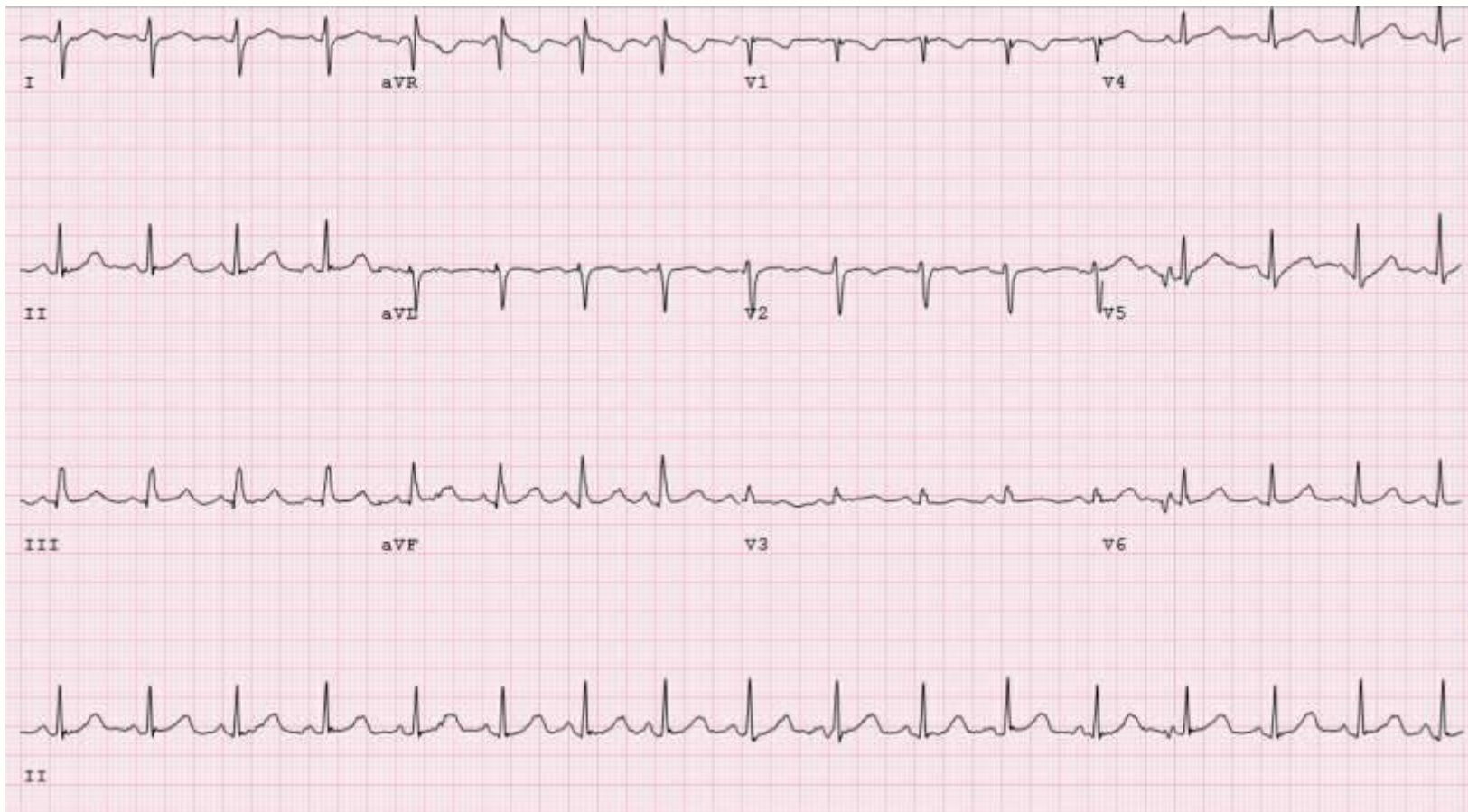
Patient GM, 13 year old female

- Outside EST report:

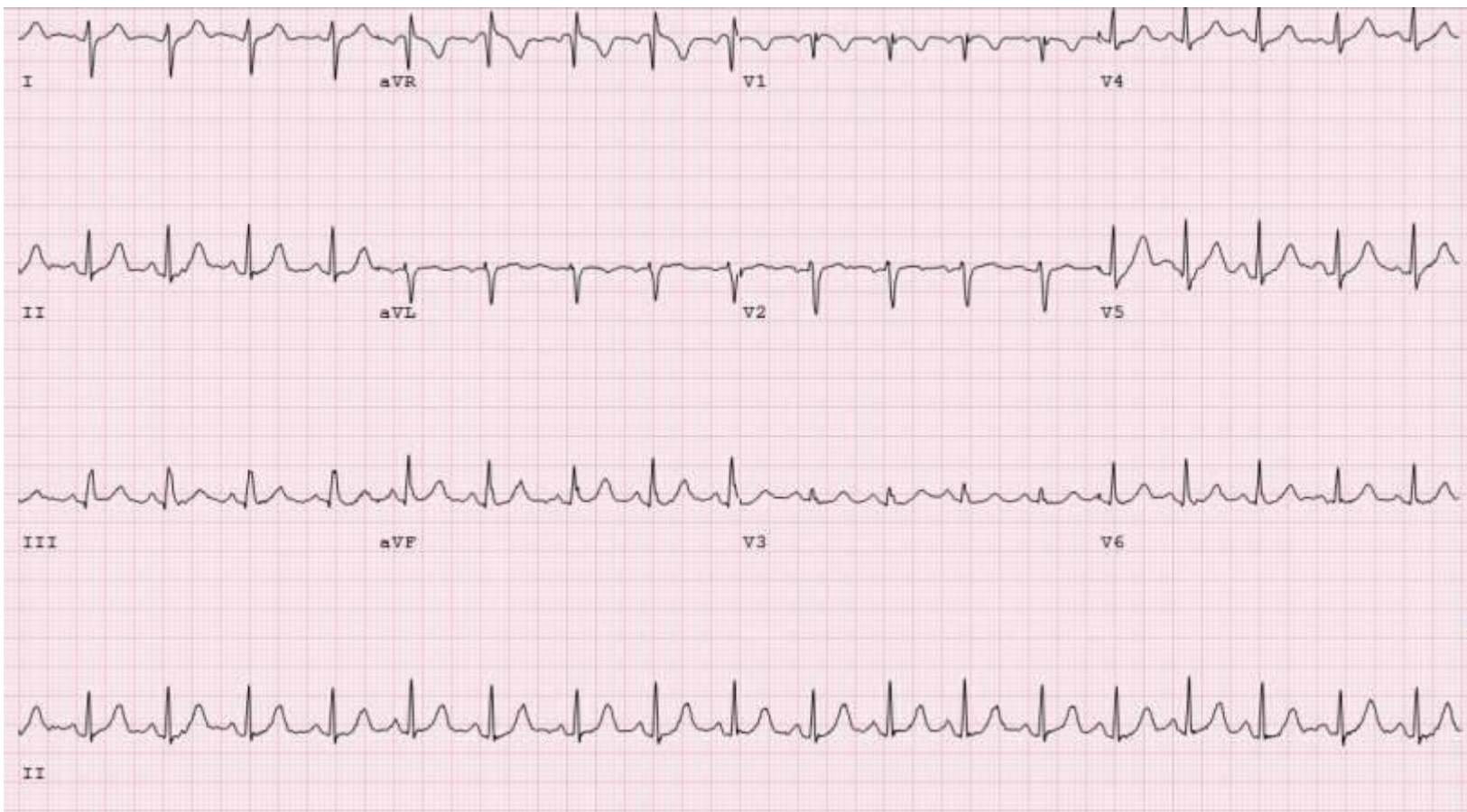
IMPRESSION:

1. Normal response to Exercise stress test.
2. No supraventricular or ventricular arrhythmia/tachycardia noted.
3. Few isolated premature ventricular contractions were seen around peak exercise
4. Patient did not report any symptoms of chest pain, shortness of breath, palpitations or near syncope during the test.

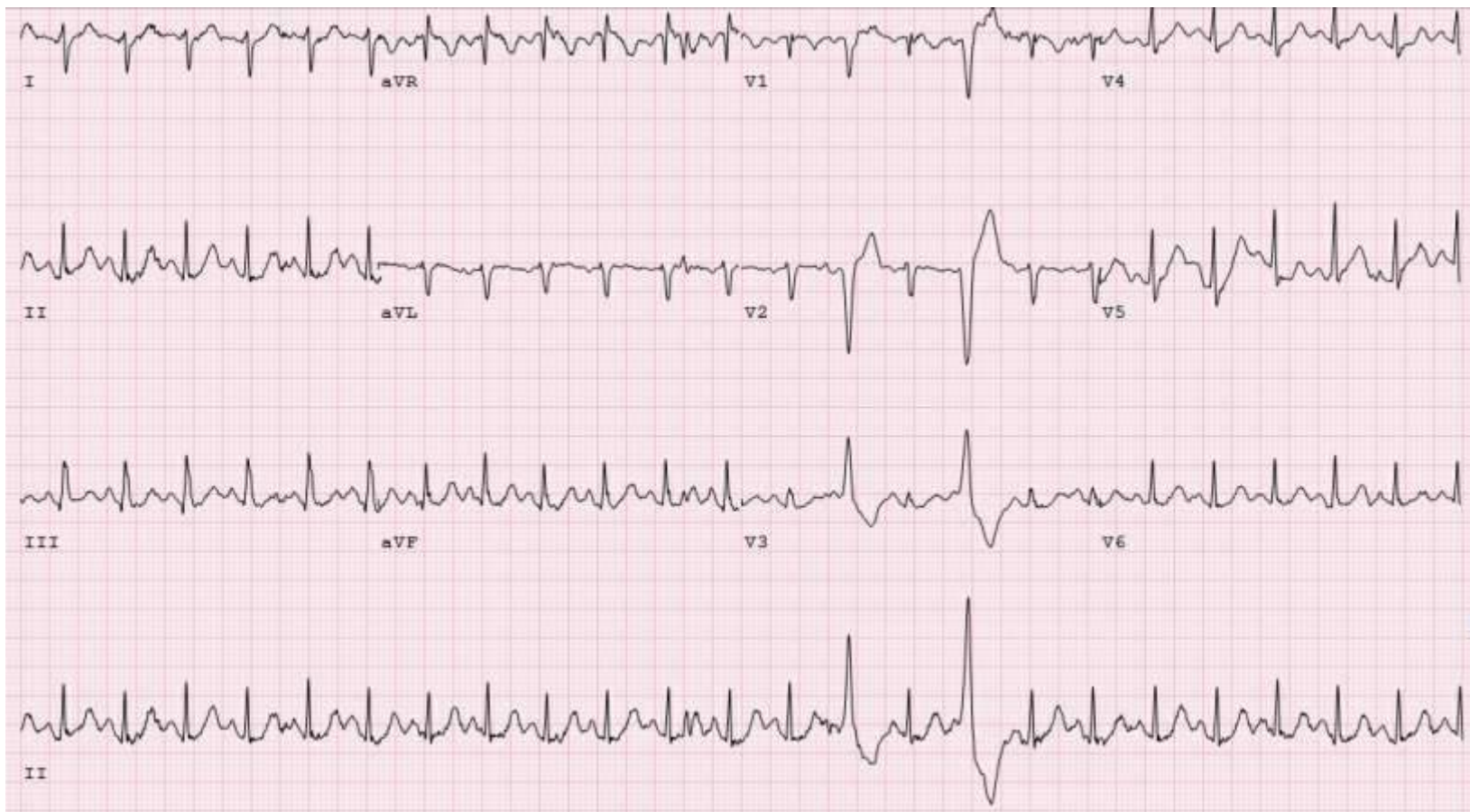ECG Stress Test - Baseline



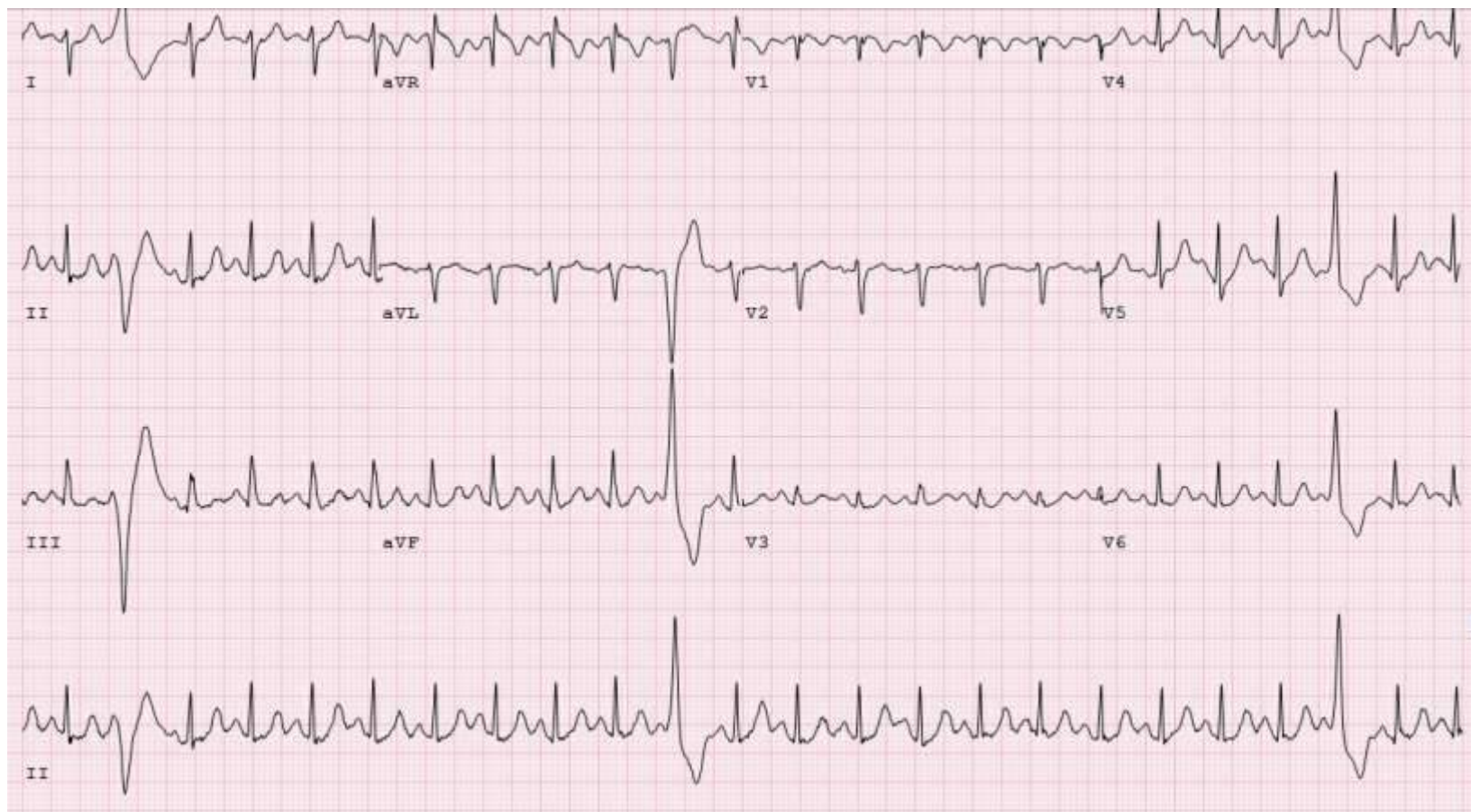
ECG Stress Test – Stage 1, 1:00



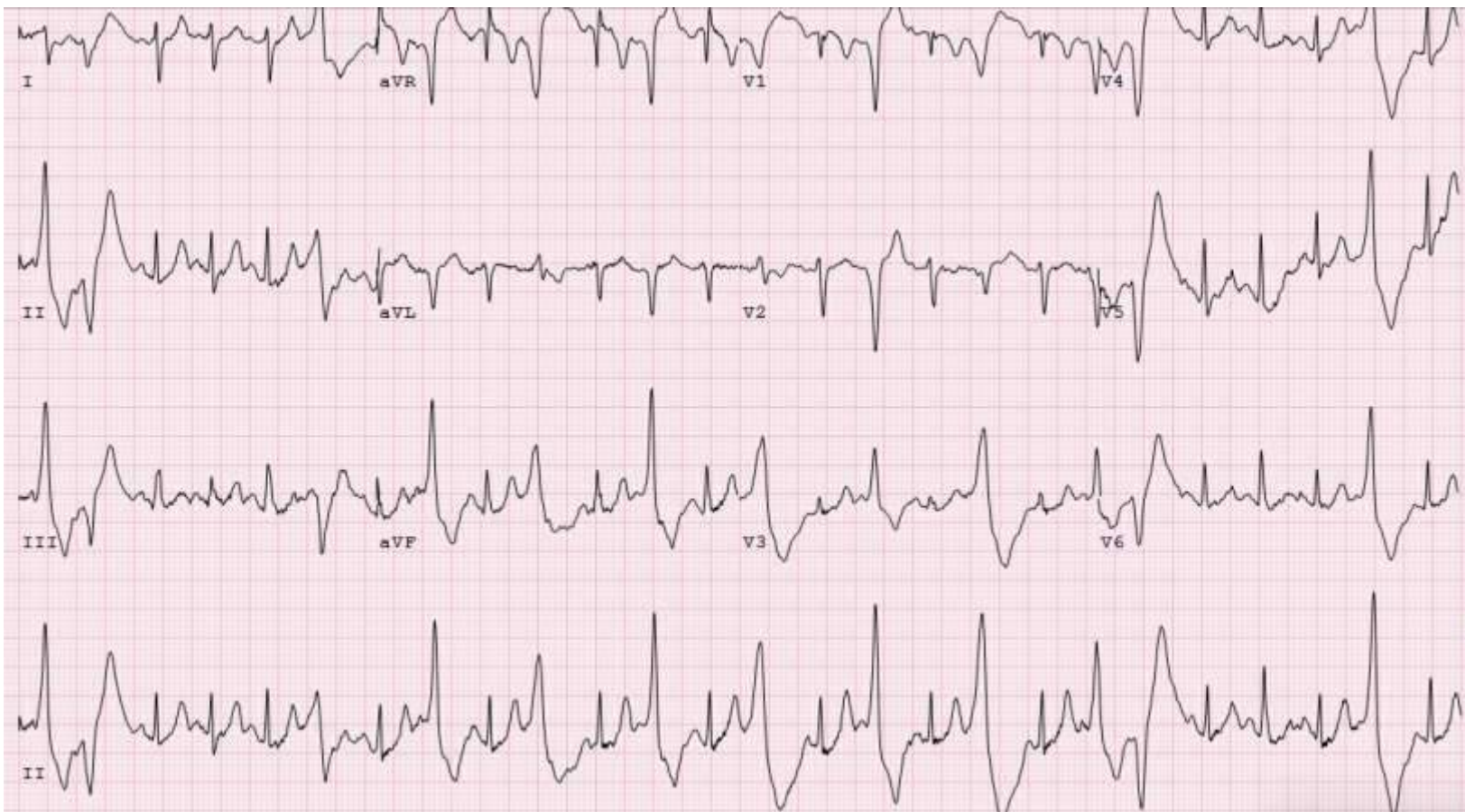ECG Stress Test – Stage 3, 5:39



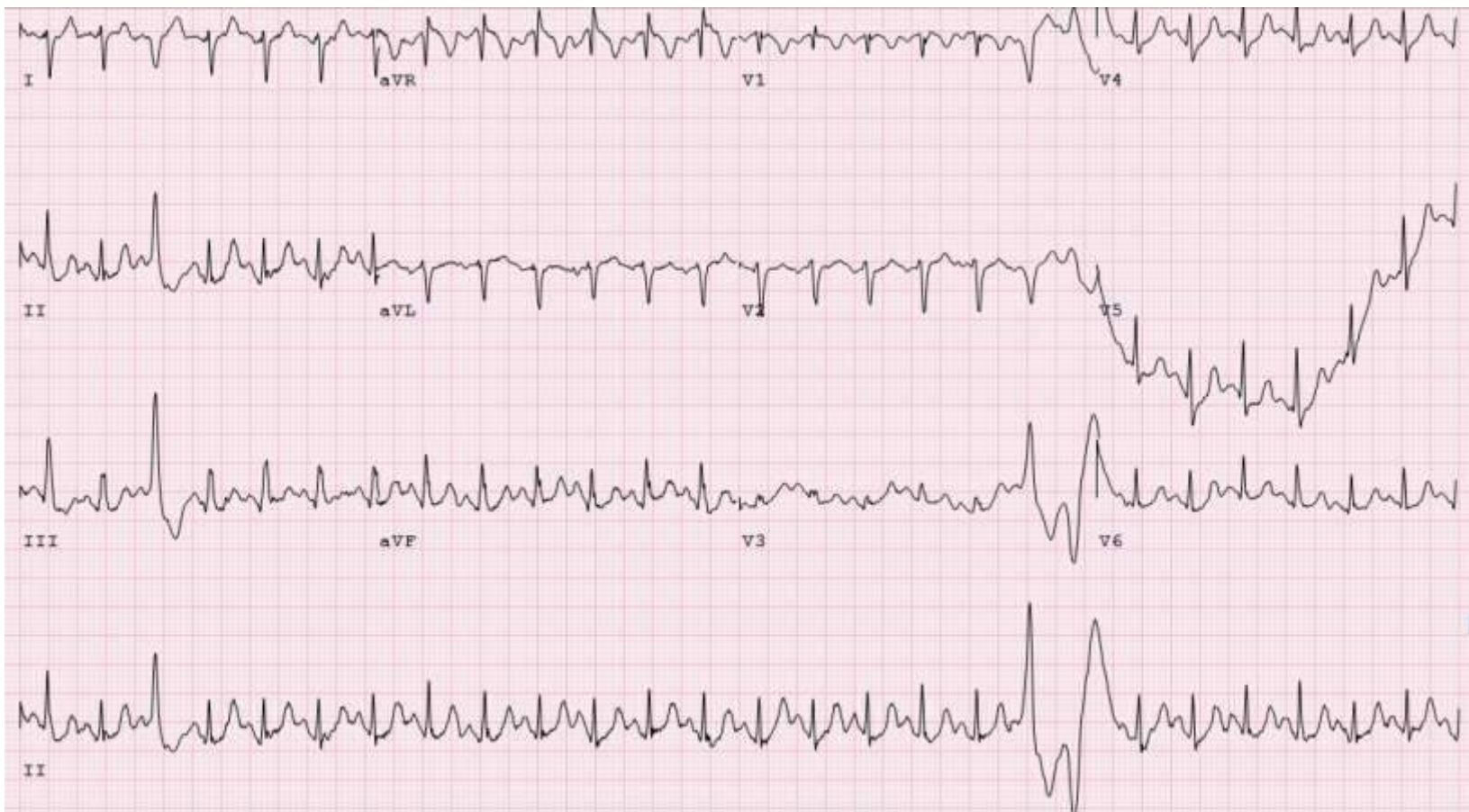ECG Stress Test – Stage 3, 5:53



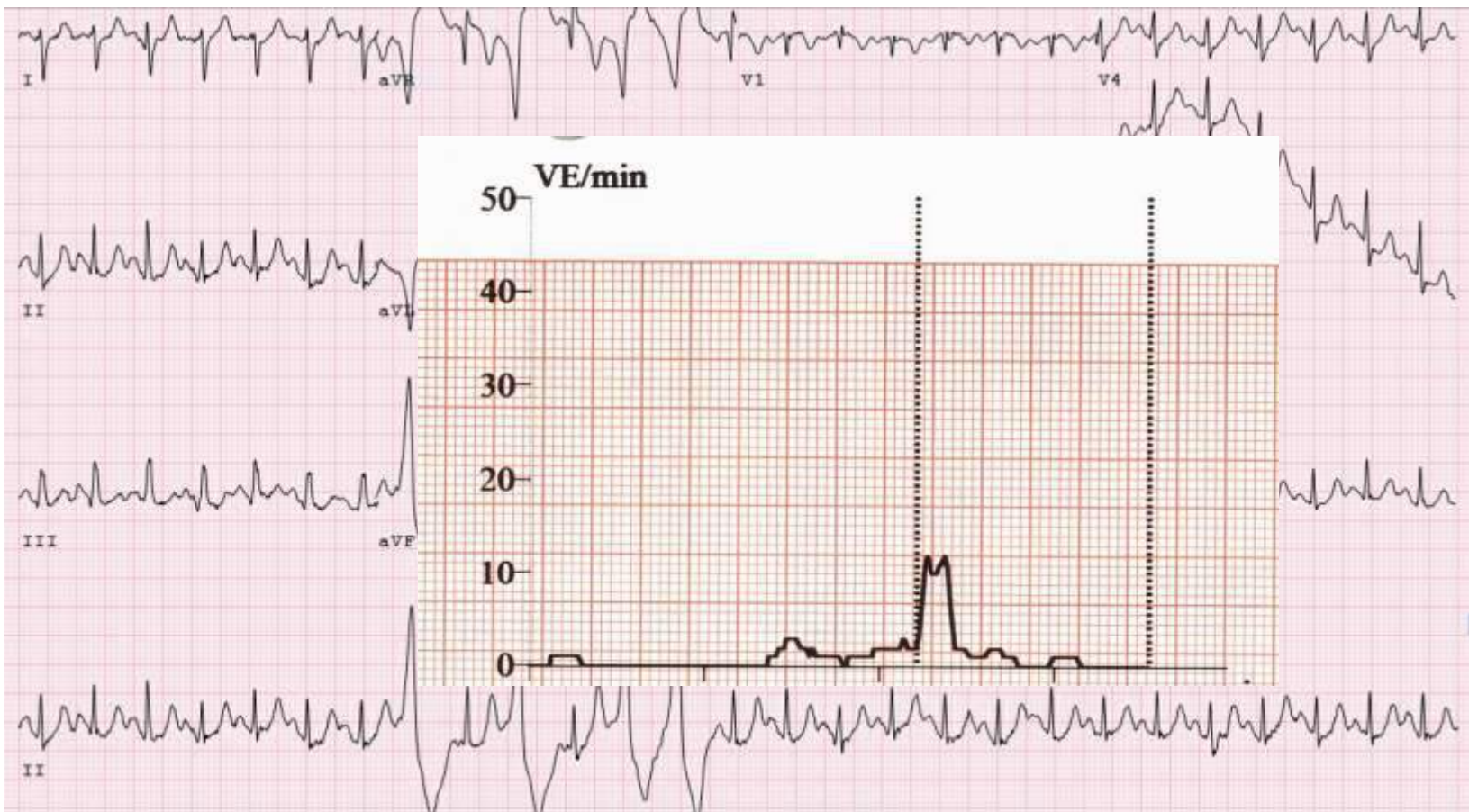ECG Stress Test – Stage 4, 6:38



ECG Stress Test – Stage 4, 7:48



ECG Stress Test – Stage 4, 7:56

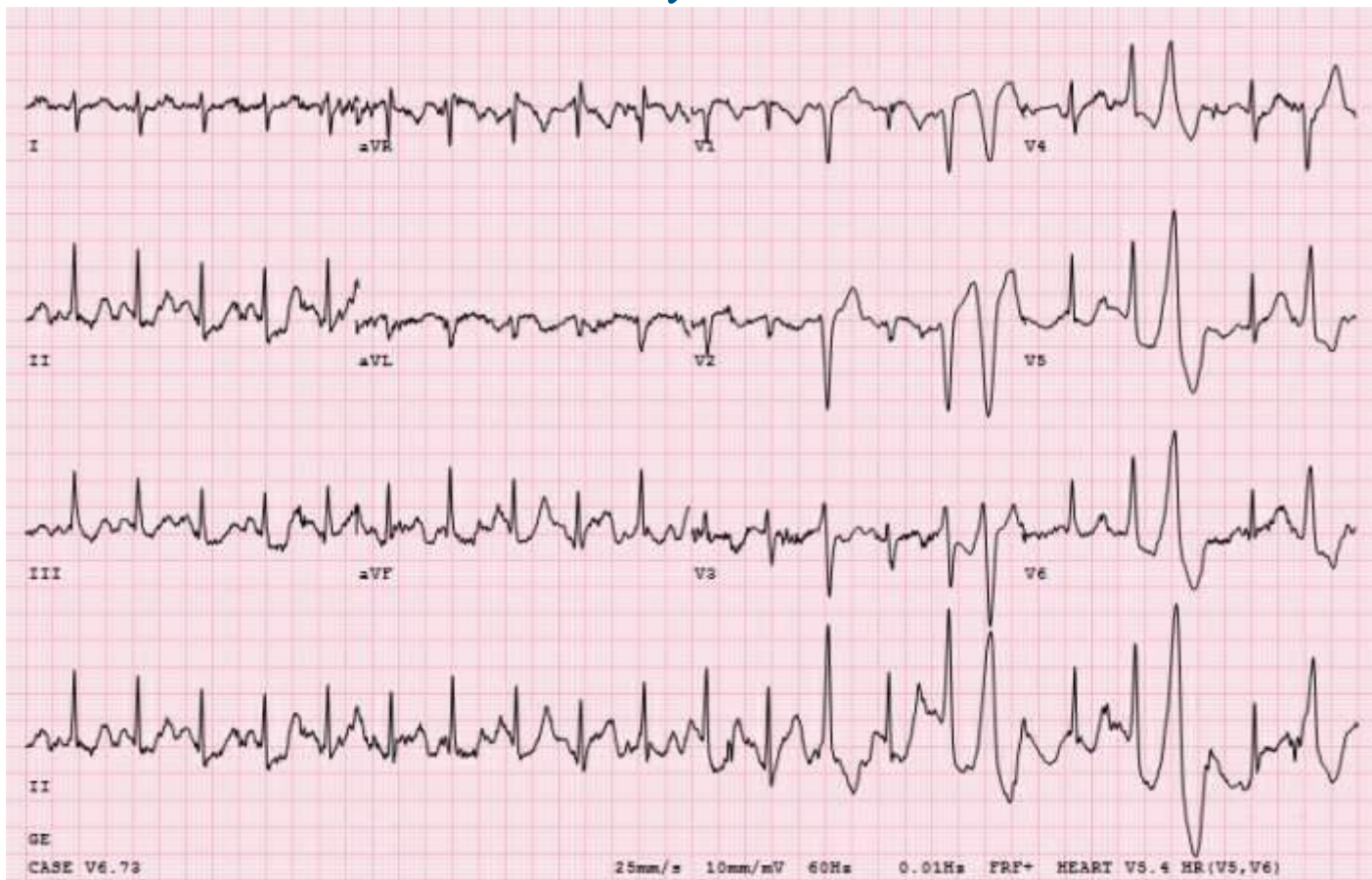

SYNCOPE IN A TEENAGER

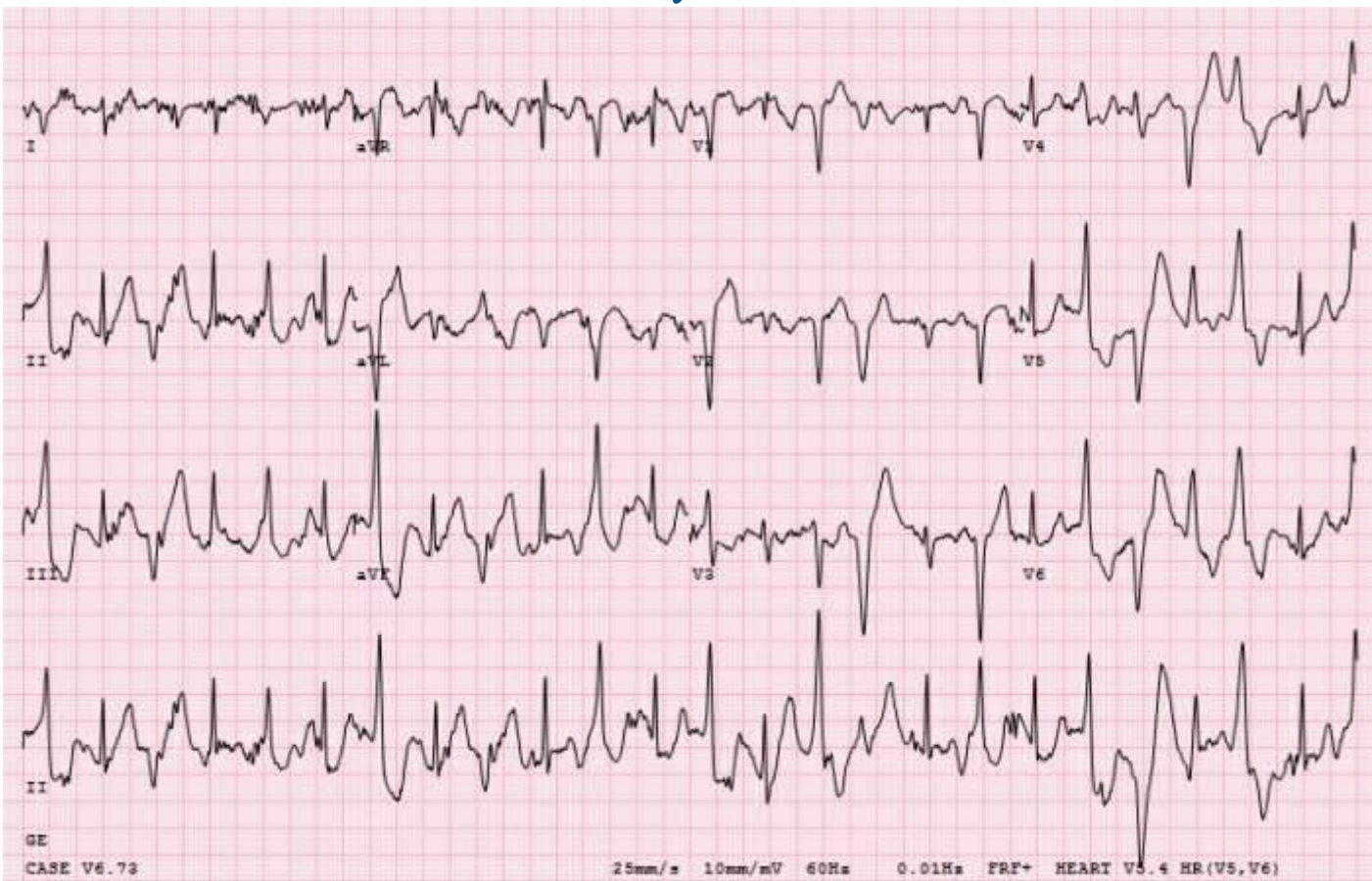Circadian Variation of Ventricular Arrhythmias in Catecholaminergic Polymorphic Ventricular Tachycardia

[Christina Y. Miyake](#), MD, MS,^{a,b} [S. Yukiko Asaki](#), MD,^a [Gregory Webster](#), MD,^c [Richard J. Czosek](#), MD,^d [Joseph Atallah](#), MD, CM, SM,^d [Kishor Avasarala](#), MD,^{e,f} [Sri O. Rao](#), MD,^g [Patricia E. Thomas](#), MD,^h [Jeffrey J. Kim](#), MD,^a [Santiago O. Valdes](#), MD,^a [Caridad de la Uz](#), MD,^a [Yunfei Wang](#), PhD,^a [Xander H.T. Wehrens](#), MD, PhD,^c and [Dominic Abrams](#), MD^{i,j}

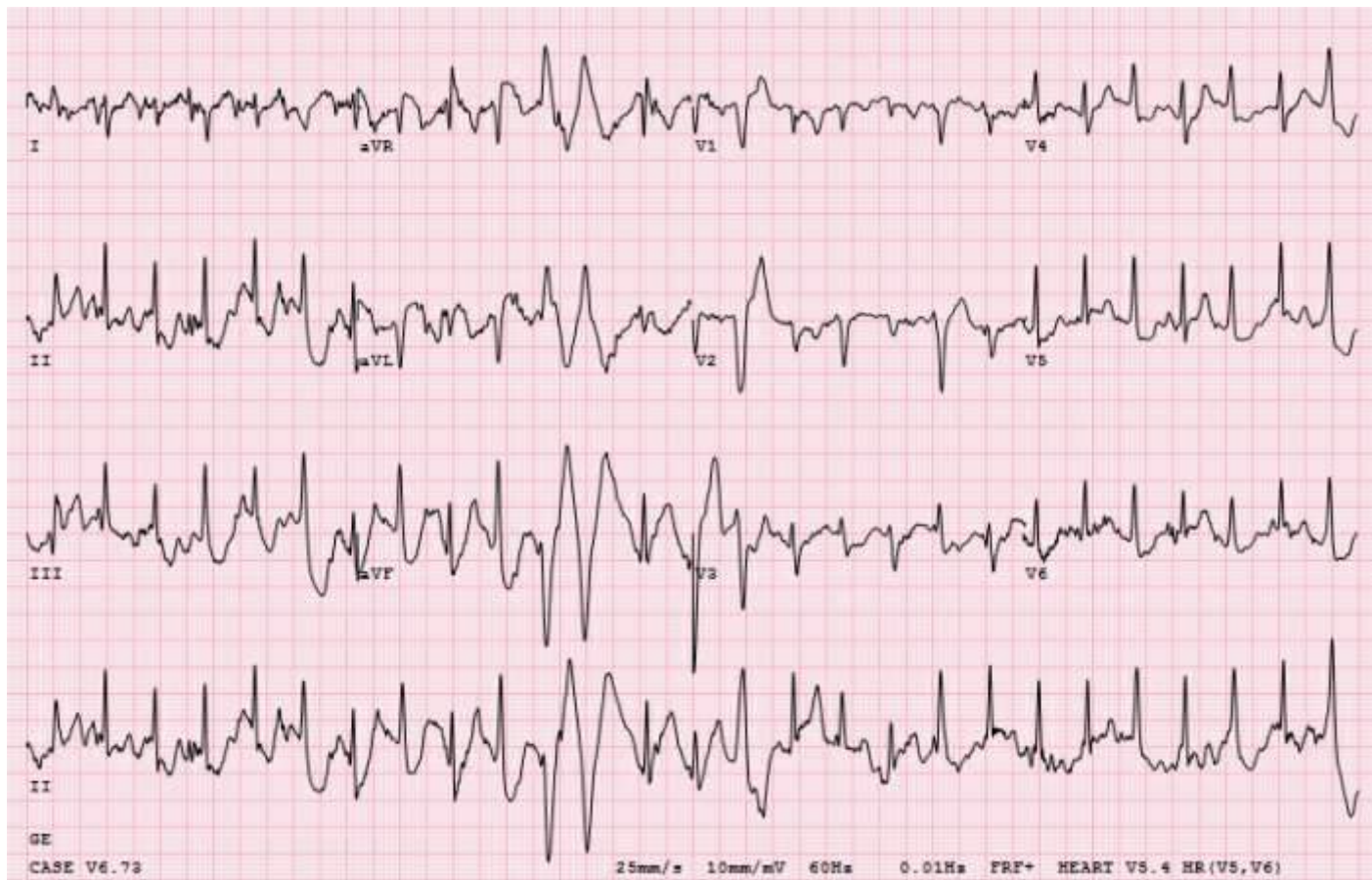REPEAT EST: 1:31, 5.7 MPH



REPEAT EST: 1:51, 6.0 MPH



REPEAT EST: 2:23, 6.0 MPH



Syncope in a teenager

Patient GM, 13 year old female

- Genetics testing revealed pathogenic variant in RYR2
- Maintained on Nadolol 40 mg BID and Flecainide 100 mg BID
 - Minimal ectopy on recent EST
- Ask questions and get help from those more knowledgeable
- Don't always trust outside evaluations/testing
- Avoid unconscious biases